



Ocular microtremor (OMT): a new neurophysiological approach to multiple sclerosis

Ciaran Bolger, Stana Bojanic, Noirin Sheahan, James Malone, Michael Hutchinson and Davis Coakley

J. Neurol. Neurosurg. Psychiatry 2000;68:639-642
doi:10.1136/jnnp.68.5.639

Updated information and services can be found at:
<http://jnnp.bmjournals.com/cgi/content/full/68/5/639>

These include:

References

This article cites 15 articles, 3 of which can be accessed free at:
<http://jnnp.bmjournals.com/cgi/content/full/68/5/639#BIBL>

2 online articles that cite this article can be accessed at:
<http://jnnp.bmjournals.com/cgi/content/full/68/5/639#otherarticles>

Rapid responses

You can respond to this article at:
<http://jnnp.bmjournals.com/cgi/eletter-submit/68/5/639>

Email alerting service

Receive free email alerts when new articles cite this article - sign up in the box at the top right corner of the article

Topic collections

Articles on similar topics can be found in the following collections

Other Neurology (3636 articles)
Multiple sclerosis (288 articles)

Notes

To order reprints of this article go to:
<http://www.bmjournals.com/cgi/reprintform>

To subscribe to *Journal of Neurology, Neurosurgery, and Psychiatry* go to:
<http://www.bmjournals.com/subscriptions/>

SHORT REPORT

Ocular microtremor (OMT): a new neurophysiological approach to multiple sclerosis

Ciaran Bolger, Stana Bojanic, Noirin Sheahan, James Malone, Michael Hutchinson, Davis Coakley

Abstract

Using a piezoelectric transducer, the frequency and pattern of ocular microtremor (OMT) between 50 normal subjects and 50 patients with multiple sclerosis were compared. Controls were age matched. All records were analysed blindly. The frequency of OMT in the normal group was 86 (SD 6) Hz, which was significantly different from that of the multiple sclerosis group (71 (SD) 10 Hz, $p < 0.001$). Those in the multiple sclerosis group with clinical evidence of brain stem or cerebellar disease ($n=36$) had an average OMT frequency of 67 (SD 9) Hz ($p < 0.001$) compared with normal ($n=86$), whereas those with no evidence of brain stem or cerebellar involvement ($n=14$) had a frequency of 81.2 (SD 6) Hz ($p < 0.05$, $n=64$). The differences between the two multiple sclerosis groups were also significant ($p < 0.001$, $n=50$). At least one abnormality (frequency and pattern) of OMT activity was seen in 78% of patients with multiple sclerosis. In the presence of brain stem or cerebellar disease 89% had abnormal records whereas in the absence of such disease 50% had abnormal records. This is the first report of the application of this technique to patients with multiple sclerosis. The results suggest that OMT activity may be of value in the assessment of multiple sclerosis.

(*J Neurol Neurosurg Psychiatry* 2000;68:639-642)

Keywords: multiple sclerosis; ocular microtremor; brain stem; physiological tremor; piezoelectric; neurophysiology

The diagnosis of multiple sclerosis is fundamentally a clinical one, requiring the demonstration of characteristic symptoms and signs of lesions disseminated within the CNS, both in time and space. The most commonly used diagnostic criteria are those of the Poser Committee.¹ Brain MRI is the single most useful diagnostic investigation in multiple sclerosis.² Serial MRI shows new lesions and exacerbation of old lesions in patients who are clinically stable.³ The exact relation between plaques and disability, however, is unclear, and the cost of MRI is considerable.⁴ As many as

5% of patients will not undergo MRI because of claustrophobia.⁴ Evoked response studies are also useful in the diagnosis of multiple sclerosis and may disclose brain stem lesions not visualised by MRI in a significant number of cases.⁵ Some authors have concluded that evoked potential techniques, although suitable for diagnostic purposes, are not appropriate for monitoring the course of multiple sclerosis or for evaluating the efficacy of therapies.^{6,7}

First described in 1934⁸ as one of three fixational eye movements, ocular microtremor (OMT) is a high frequency, low amplitude, physiological tremor of the eyes.⁹ The tremor is present even when the eye is at rest and is due to the constant activity of brain stem oculomotor units.⁹ The OMT signal appears as an irregular oscillatory movement with intermittent burst-like components.¹⁰ After initial studies in the 1970s¹¹ the clinical interest in OMT has centred on its use in the assessment of the comatose patient, with broad agreement among authors of its prognostic value.^{9,12}

The aim of this study was to investigate the potential use of OMT recordings as a simple, bedside complementary test in the evaluation of patients with multiple sclerosis.

Patients and methods

PATIENTS

Fifty three patients with a diagnosis of multiple sclerosis¹ made by a qualified neurologist were studied. Three were excluded because of the presence of gaze palsies/internuclear ophthalmoplegia, which of themselves would interfere with OMT. The mean age of the patients was 41.8 (SD 14) years. Each patient was matched for sex and age, within 2 years, with a normal healthy volunteer, mean age 41.6 (SD 14.7) years. The mean duration of disease was 9.32 (SD 6.25) years. In both patients with multiple sclerosis and volunteers the female to male ratio was 2.13:1. None of the patients or controls were on medication which might effect brain stem function.

Thirty six patients had clinical evidence of brain stem or cerebellar disease, mean age 42.9 (SD 12.8) years, whereas 14 did not, mean age 40 (SD 12.5) years. The presence or absence of brain stem or cerebellar disease was decided on clinical examination by the consultant concerned before the recording or analysis of

Mercer's Institute for Research on Ageing, St James's Hospital, Dublin
N Sheahan
J Malone
D Coakley

Department of Neurosurgery, Frenchay Hospital, Frenchay Park Road, Bristol BS16 1LE, UK
C Bolger
S Bojanic

Department of Neurology, Adelaide Hospital, Dublin
M Hutchinson

Correspondence to: Mr Ciaran Bolger

Received 8 December 1998 and in revised form 20 July 1999
Accepted 5 August 1999

Results of the frequency analysis for the subjects studied

Subjects	No	Age	Frequency	SD
Healthy control	50	41.6	86.15	6.3
MS	50	41.8	71.3***	10.53
MS with evidence of brain stem disease	36	42.9	67.09*	8.9
MS without evidence of brain stem disease	14	39.8	81.98*	5.7

* $p < 0.05$; *** $p < 0.001$.
MS=Multiple sclerosis.

OMT records and all subjects underwent MRI of the head.

Informed consent was received from all patients and volunteers. The study was approved by the federated Dublin voluntary hospitals ethics committee.

METHODS

Ocular microtremor was recorded using the piezoelectric strain gauge technique developed by Bengi and Thomas.¹³ The piezoelectric element was mounted in a perspex rod and its tip was covered in silicone rubber. The perspex rod was mounted on a head frame and lowered directly to the scleral surface which was anaesthetised with 1% proxymethacaine hydrochloride solution. The subject was asked to keep the head still throughout the recording but no means of head restraint were used. Probe placement was judged by visual inspection and by listening to the signal being recorded, using audio cassette headphones. The eye lids were retracted using adhesive tape.

During recording the subject lay supine, looking straight ahead in a normally lit room. The signal generated was amplified and stored on magnetic tape for later retrieval and analysis on an ECG tape analyser (Reynolds Medical (RM) Pathfinder 3 and RM TP-Thermal Printer). All records were made at the patients' bedside or in the outpatient clinic.

A recording of between 30 seconds and one minute of OMT activity was taken.¹⁴ As with previous series no adverse reactions to the test procedure were reported from either patients or volunteers. After a recording session the probes were soaked in sodium hypochlorite

(concentration 500 ppm) for 10 minutes, for sterilisation purposes, before being used again.¹⁵

RECORD ANALYSIS

The OMT activity was assessed in terms of the frequency of the tremor and the tremor pattern. Normal OMT has a distinct pattern consisting of an irregular baseline tremor superimposed on which are sinusoidal episodes of regular activity, termed bursts. The bursts are easily distinguishable, possessing a greater amplitude than the rest of the microtremor and a packet-like appearance against the baseline tremor. In the absence of such a normal regular pattern a record was declared abnormal, whether or not the overall frequency was within the normal range. Previous studies by Bolger have shown a correlation coefficient of reliability of 0.84 and 0.97 for mean peak count frequency and for pattern analysis respectively by different observers.¹⁶ Analysis of records was by visual inspection by an investigator who was unaware of the clinical status of the subject. The peaks occurring per unit time on a printed record are counted. This provides a good estimate of the high frequency component of any random signal,¹⁷ particularly OMT.¹⁰

Results

ANALYSIS OF FREQUENCY

The results of the frequency analysis for the healthy controls and patients with multiple sclerosis are given in the table and the figure. The mean frequency of OMT in the control group was 86.15 (SD 6.3) Hz. The mean frequency of OMT in patients with multiple sclerosis was 71.3 (SD 10.53) Hz, which is significantly less than the controls ($p < 0.001$). If only those subjects with evidence of brain stem cerebellar disease are considered the difference is more marked ($p < 0.001$), the mean frequency of these subjects being 67.09 (SD 8.9) Hz. Comparison of the frequencies of OMT between the normal controls and patients with multiple sclerosis without brain stem or

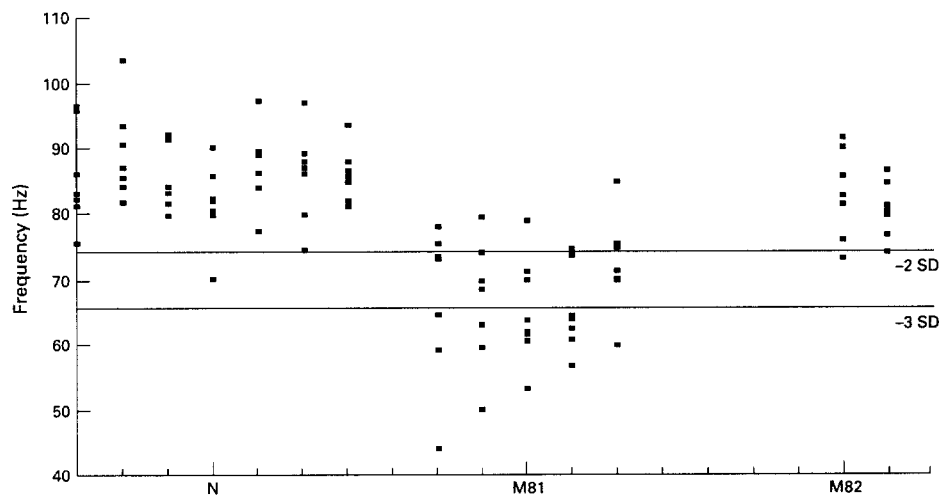


Figure 1 Scattergram of the ocular microtremor frequency in normal controls (n). Patients with multiple sclerosis with evidence of brain stem or cerebellar disease (MS1) and patients with multiple sclerosis without evidence of brain stem or cerebellar disease (MS2). The 2 and 3 SD levels refer to the control population.

cerebellar disease also shows a significant but less marked difference. Within the multiple sclerosis group, patients with evidence of brain stem or cerebellar disease (mean frequency 67.09 (SD 8.9) Hz) have a significantly lower frequency of OMT than those patients without evidence of such disease (mean frequency 81.98 (SD 5.7) Hz), $p < 0.005$.

If the mean OMT frequency -2 SD is taken as the lower limit of normal, then of the 50 patients with multiple sclerosis studied, 28 had an abnormally low tremor frequency (56%, figure). If only those patients with clinical evidence of brain stem or cerebellar disease are considered 27 of 36 patients showed low tremor frequency (75%). Only one of 14 patients without clinical evidence of brain stem or cerebellar disease had abnormally low tremor frequency (7%).

ANALYSIS OF PATTERN

Thirty six of 50 patients with multiple sclerosis were judged to have an abnormal tremor pattern (72%). Of those patients with clinical evidence of brain stem or cerebellar disease 29 (of 36) had an abnormal tremor pattern (80%) and seven of 14 without brain stem or cerebellar disease had an abnormal pattern (50%). One of the 50 normal subjects had an OMT record that was labelled abnormal on blind analysis (2%).

COMBINED ANALYSIS

At least one abnormality of OMT activity was seen in 39 of 50 patients with multiple sclerosis (78%). Of those 36 patients showing clinical evidence of brain stem or cerebellar disease 32 had OMT abnormalities (89%) and of the 14 patients with no evidence of such lesions seven (50%) demonstrated abnormalities of tremor activity. By contrast, only one of 50 normal records was considered abnormal (2%).

No significant association between abnormal eye tremor and disease or disability could be demonstrated that was independent of the effects of brain stem or cerebellar disease.

Discussion

In this study, the identification of abnormality in 78% of all our patients, and in 89% of those patients with clinical evidence of brain stem or cerebellar disease compares favourably with other neurophysiological techniques. When applied to patients with clinically definite multiple sclerosis, visual evoked potentials have been reported to be abnormal in 85% of patients with clinically definite multiple sclerosis and 37% of those with probable or possible multiple sclerosis.¹⁸ Brain stem auditory evoked potentials (BAEPs) were abnormal in 67% of patients with clinically definite multiple sclerosis, 41% with probable multiple sclerosis, and 30% with possible multiple sclerosis, and in about 20% to 50% of patients in all categories with no clinical signs of brain stem dysfunction.¹⁹ A recent study by Soustiel *et al*²⁰ found abnormal BAEPs in 72% of patients with definite multiple sclerosis. Somatosensory evoked potentials may be abnormal in up to 80% of patients.⁶

The analysis of physiological tremor provides sensitive information on the activity of the motor units generating that tremor.²¹ Because tonic oculomotor unit activity is dependent on the numerous tonic inputs to the motor units, lesions in any of these inputs may effect the recorded tremogram.⁸ The high frequency nature of the tremor should also enhance its sensitivity when assessing patients with multiple sclerosis as demyelinated nerves exhibit a particularly impaired ability to respond to rapid stimulation.²¹

The recording of ocular microtremor provides a new neurophysiological technique for the assessment of patients with multiple sclerosis. Only one of the control subjects was thought to have an abnormal OMT pattern on blind analysis of his record. This subject had a normal clinical examination and had no evidence of neurological disease. He was, however, the oldest tested, at 70 years of age. The same subject also had the lowest OMT frequency recorded from a normal subject (70 Hz). In more recent studies on 105 normal volunteers we have shown a significant fall in OMT frequency after 70 years of age.²² In this study 206 OMT recordings were made and in no case were adverse effects seen. Unlike other electrophysiological methods the technique is rapid and requires a minimum of patient cooperation. Including time for setting up; a recording session takes 10 minutes with 30 seconds of tremor record being required for analysis.¹⁴ The equipment is portable and recordings may be made at the patients' bedside as easily as in the laboratory.

The results presented here are encouraging. The extent of the abnormalities detected would indicate that this method may be of value in assessing patients with apparently single lesions. However, for this technique to be applied clinically further studies are required to assess patients in "clinically possible" or "clinically probable" groups who then go on to develop clinically definite disease. More information may be derived from the application of frequency spectral analysis to patient records and this is being studied.

This work was sponsored by the Health Research Board and Nadcorp Ireland Limited. We are grateful to Dr E A Martin, Department of Neurology, Adelaide Hospital, Dublin, for his help in preparation of the text.

- Poser CM, Paty DW, Scheinberg L, *et al*. New diagnostic criteria for multiple sclerosis: guidelines for research protocols. *Ann Neurol* 1983;13:227-31.
- Miller DH, McDonald WI. Neuroimaging in multiple sclerosis. *Clinical Neuroscience* 1994;2:215-24.
- McFarland HF, Frank JA. Using gadolinium-enhanced magnetic resonance imaging lesions to monitor disease activity in multiple sclerosis. *Ann Neurol* 1992;32:758-66.
- Erickson BJ, Noseworthy JH. Value of magnetic resonance imaging in assessing efficacy in clinical trials of multiple sclerosis therapies. *Mayo Clin Proceedings* 1997;72:1080-9.
- Cosi V, Bergamaschi R, Citterio A, Callieco R. Brainstem impairment in multiple sclerosis: An assessment by multimodal evoked potentials. *Ital J Neurol Sci* 1989;10:157-61.
- Aminoff MJ, Davis SL. Serial evoked potential studies in patients with definite multiple sclerosis. *Arch Neurol* 1985;41:197-202.
- Anderson DC, Slater GE. Evoked potentials to test a treatment of chronic multiple sclerosis. *Arch Neurol* 1987;44:1232-6.
- Alder FH, Fliegelman F. Influence of fixation on the visual acuity. *Arch Ophthalmol* 1934;12:475-83.

- 9 Coakley D. *Minute eye movement and brainstem function*. CRC Press, Florida, 1983.
- 10 Sheahan N, Coakley D, Hegarty F, et al. Ocular microtremor measurement system: design and performance. *Med Biol Eng Compu* 1993;31:205-212.
- 11 Abakumova LY, Shakhnovich AR, Thomas JG. An investigation of the correlation between abnormal patterns of OMT and abnormal pupil reflex in neurological patients. *J Neurol Sci* 1975;26:469-518.
- 12 Shakhnovich AR, Thomas JG, Dubova SB, et al. The prognosis of the outcome of comatose states. *Resuscitation* 1980;8:243-55.
- 13 Bengi H, Thomas JG. Three electronic methods for recording ocular tremor. *Med Biol Eng* 1968;6:171-8.
- 14 Bolger C, Sheahan N, Coakley D, et al. High frequency eye tremor: reliability of measurement. *Clinical Physics and Physiological Measurement* 1992;13:151-9.
- 15 Nagington J, Sutehall GM, Whipp P. Tonometer disinfection and viruses. *Br J Ophthalmol* 1983;67:674-6.
- 16 Bolger C. *Ocular microtremor: reliability of measurement, physiological variation, and neurogenic origin* [PhD thesis]. Dublin: Trinity College Dublin, 1994.
- 17 Smith JD. *Vibration measurement and analysis*. London: Butterworths, 1989.
- 18 Chiappa KH. Pattern-shift visual evoked potentials: interpretation. In: Chiappa KD, ed. *Evoked potential in clinical medicine*. 2nd ed. New York: Raven Press, 1990:111-54.
- 19 Chiappa KH. Brain stem auditory evoked potential: interpretation. In: Chiappa KH, ed. *Evoked potentials in clinical medicine*. 2nd ed. New York: Raven Press, 1990:223-84.
- 20 Soustiel JF, Hafner H, Chistyakov AV, et al. Brainstem trigeminal and auditory evoked potentials in multiple sclerosis: physiological insights. *EEG and Clinical Neurophysiology* 1996;100:152-7.
- 21 Freund AJ, Hefter H, Homberg V, et al. Differential diagnosis of motor disorders by tremor analysis. In: Findlay IJ, Capildeo R, eds. *Movement disorders: tremor*. Mc Milland, London, 1984.
- 22 Bolger C, Bojanic S, Sheahan N, et al. Dominant frequency content of ocular microtremor from normal subjects. *Vision Research* 1999;39:1485-8.